

In a third series, 4 patients (1.4%) of 281 liver transplant procedures developed areflexic quadriplegia immediately after OLT, which was attributed to a myosin-loss myopathy confirmed by muscle biopsy (9), as in the two previous series. Myopathy was associated with renal failure and a number of reoperations. Despite of these complications, the prognosis for recovery was good.

As for mononeuropathies, quadriplegia seems to occur in less than 2% up to 10% of patients after OLT. The motor deficit was attributed to necrotizing myopathy in the three previous series, but seems that peripheral neuropathy is also associated with the disease, as shown in this study. Acute myopathy or CIP are probably too restrictive terms for a neuromyopathic involvement. The myopathic part of the syndrome may be responsible for rapid recovery, whereas the neuropathic part must lead to more prolonged handicap.

CIP was diagnosed in our patients, and CIP is mainly associated with sepsis and multiple organ failure (2). In our series, sepsis did not occur and could not explain the development of neuropathy. However, two patients exhibited renal and irreversible hepatic graft failure, whereas the third patient had only transient hepatic failure. Organ failure is probably the first-line cause of acquired paralysis in patients after OLT. The use of high doses of corticosteroids may be also involved, because it is a well known factor for myopathy in ICU patients (8). Prolonged administration of neuromuscular blocking agents in the ICU has been discussed among CIP causative factors. Because no patient was treated with muscle relaxants in our series, this factor can be excluded. Finally, the role of tacrolimus in subacute peripheral neuropathy occurring in patients who underwent OLT has been reported (10). In our study, the three patients received ta-

colimus; however, its neurotoxic effect seems improbable because clinical improvement of neuropathy was seen in all patients despite tacrolimus administration.

In summary, acute paralysis may develop early after OLT in case of allograft failure, without any concomitant sepsis. An axonal polyneuropathy is involved together with probable myopathic changes. Acute hepatic graft failure seems to be the main risk factor.

REFERENCES

1. Bolton C, Gilbert J, Fhahn A, et al. Polyneuropathy in critically ill patients. *J Neurol Neurosurg Psychiatry* 1984; 47: 1223.
2. Witt NJ, Zochodne DW, Bolton CF, et al. Peripheral nerve function in sepsis and multiple organ failure. *Chest* 1991; 99: 176.
3. Leijten F, de Weerd A, Poortvliet D, et al. Critical illness polyneuropathy in multiple organ dysfunction syndrome and weaning from the ventilator. *Intensive Care Med* 1996; 22: 856.
4. DeJonghe B, Cook D, Sharshar T, et al. Acquired neuromuscular disorders in critically ill patients: a systematic review. *Intensive Care Med* 1998; 24: 1242.
5. Wijdicks EFM, Litchy WJ, Wiesner RH, et al. Neuromuscular complications associated with liver transplantation. *Muscle Nerve* 1996; 19: 696.
6. Campellone JV, Lacomis D, Giuliani MJ, et al. Mononeuropathies associated with liver transplantation. *Muscle Nerve* 1998; 21: 896.
7. Grant AJ, Buckels JA, Neuberger J. Symptomatic carpal tunnel syndrome after orthotopic liver transplantation: a retrospective analysis. *Transplantation* 1998; 65: 442.
8. Campellone JV, Lacomis D, Kramer DJ, et al. Acute myopathy after liver transplantation. *Neurology* 1998; 50: 46.
9. Miro O, Salmeron JM, Masanes F, et al. Acute quadriplegic myopathy with myosin-deficient muscle fibres after liver transplantation: defining the clinical picture and delimiting the risk factors. *Transplantation* 1999; 67: 1144.
10. Bronster DJ, Yonover P, Stein J, et al. Demyelinating sensorimotor polyneuropathy after administration of FK506. *Transplantation* 1995; 59: 1066.

ULTRASOUND-GUIDED PERCUTANEOUS THROMBIN INJECTION FOR TREATMENT OF EXTRARENAL PSEUDOANEURYSM AFTER RENAL TRANSPLANTATION

MANUEL REUS,^{1,3} DOLORES MORALES,¹ VICTORIA VÁZQUEZ,¹ SANTIAGO LLORENTE,³ AND JOSÉ ALONSO¹

A patient who received two kidney transplants was placed on hemodialysis after failure of both grafts. He had complained of abdominal pain during the preceding month and was found to have a pulsating mass in his right pelvic region. Computed tomography and color Doppler studies showed a large pseudoaneurysm of the common iliac artery. We describe the treatment of this lesion by the use of ultrasound-guided thrombin injection. To the best of our knowledge, this is the first report regarding the use of ultrasound-guided

percutaneous thrombin injection for treatment of such a pseudoaneurysm.

Extrarenal pseudoaneurysms in patients who receive renal transplants are rare. However, when they occur, the consequences may be serious because of the potential for rupturing, which may in turn produce significant hemorrhage (1). Ultrasound (US)-guided percutaneous thrombin injection has recently been introduced as a viable technique in the treatment of iatrogenic femoral pseudoaneurysms (2).

We describe a new and successful application of this technique in the treatment of a large extrarenal pseudoaneurysm in a patient on hemodialysis after the failure of two transplanted kidneys.

CASE REPORT

A 42-year-old man with end-stage renal failure of unknown cause was placed on hemodialysis in 1977. After 8 years on dialysis, he received his first cadaveric renal transplant in

¹ Service de Radiology.

² Service de Nephrology.

³ Address correspondence to: Dr. D. Manuel Reus Pintado, Servicio de Radiología, Hospital Universitario "Virgen de la Arrixaca," Crta. Murcia-Cartagena, 30.120 El Palmar, Murcia, Spain. E-mail: mreus@hvax.insalud.es.

Received 30 October 2001.

Revision Received 11 December 2001. Accepted 24 March 2002.

DOI: 10.1097/01.TP.0000019426.37275.50

his right iliac fossa. The donor artery was anastomosed end-to-side to the recipient common iliac artery. After 40 days, the patient showed signs of severe rejection, although he had a good response to polyclonal antibodies (antithymocyte globulin). Four months after the transplantation, the patient showed a deterioration in renal function together with arterial hypertension, which was difficult to control. After a few weeks, because of failure of the graft, the patient was placed on hemodialysis.

In October 1991, the patient received a second cadaveric kidney transplant in his left iliac fossa. After 20 days, there were signs of severe transplant rejection with a significant vascular response, which did not respond to steroids or monoclonal antibodies (OKT₃). Hemodialysis was again required.

After approximately 1 month, the patient presented with pain in his right iliac fossa. On examination, a pulsating mass was noted in the patient's right pelvic area. A contrast-enhanced abdominal computed tomography scan was performed. The study revealed a pseudoaneurysm that was 7 cm in diameter and had a volume of 53 cm³ (Fig. 1). The neck of the lesion measured 3.8 cm long by 7 mm wide. The apparent origin of the pseudoaneurysm was from the anastomosis of the right common iliac artery with the transplant renal artery. Color Doppler US confirmed the existence of a pseudoaneurysm with simultaneous bidirectional flow within its lumen (Fig. 2). Transcatheter embolization was recommended, but the patient refused this. Consequently, the patient was offered an alternative treatment: US-guided percutaneous occlusion by means of thrombin injection. Before the thrombin injection, the femoral pulse in the right inguinal region was taken, as were pulse readings in the right dorsalis pedis and right posterior tibial arteries. The skin of the right iliac fossa was prepared with povidone iodine (Betadine; Asta Medica, Madrid, Spain) and covered with a sterile drape. A 3.5-inch 22-gauge spinal needle (B/Braun, Melsungen, AG) was introduced into the cavity of the pseudoaneurysm under continuous US control (Powervision 6000, Toshiba, Japan) using a convex probe of 6 MHz wrapped in a sterile cover. Grey scales were used until the tip of the needle was located

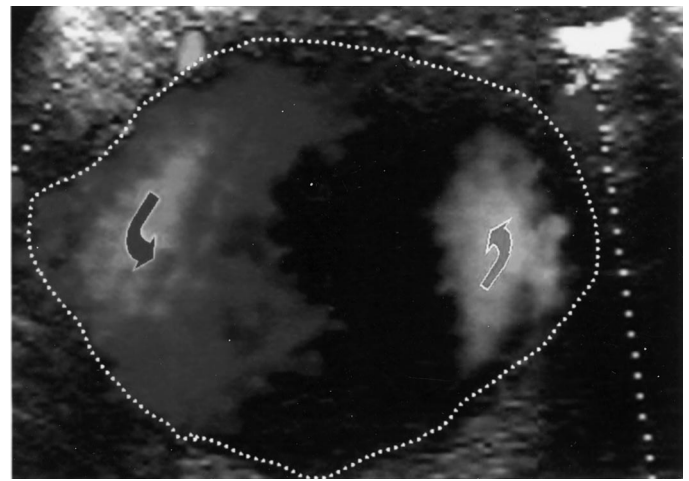


FIGURE 2. Color Doppler ultrasound (US) scan reveals typical to-and-fro blood flow pattern (*curved arrows*) within the lumen of the pseudoaneurysm (*dotted line* is the lumen of the pseudoaneurysm).

in the periphery of the pseudoaneurysm, trying to situate it as far as possible from the neck. The injection of 5 mL of bovine thrombin (1000 U/mL Thrombin, Ciamsa Médica S.L., Barcelona, Spain) was commenced as a slow bolus of 0.1 to 0.3 mL over 3 sec, under constant color Doppler control. After 45 sec, once the 3 mL (3000 U) had been injected, a 75% occlusion of the pseudoaneurysm was confirmed. A repeat injection of 2 mL (2000 U) of thrombin was therefore required to achieve total occlusion. A color Doppler study demonstrated that the right common iliac artery and vein were patent (Fig. 3).

A total dose of 5000 U of thrombin had been required for complete occlusion of the pseudoaneurysm. The whole procedure lasted approximately 90 sec. A normal arterial pulse was confirmed in both the proximal and distal arteries. A color Doppler study performed the following day showed no

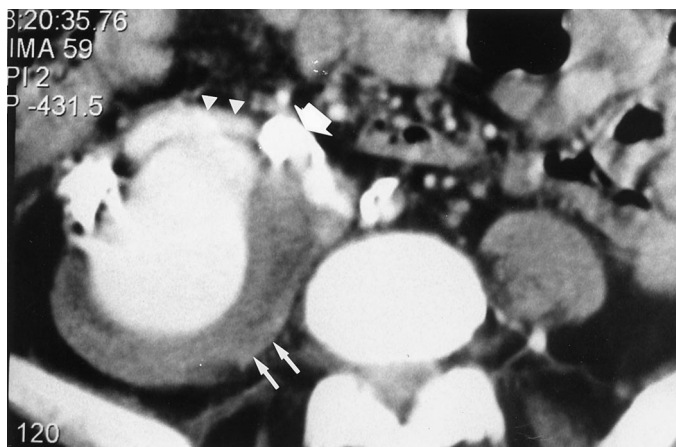

FIGURE 1. Contrast-enhanced CT scan of the pelvis shows a 7-cm pseudoaneurysm with enhancement of its lumen and nonenhancing wall of 1.5-cm thickness (*arrows*). The neck of the pseudoaneurysm (*arrowheads*) arises from the right common iliac artery (*large arrow*).

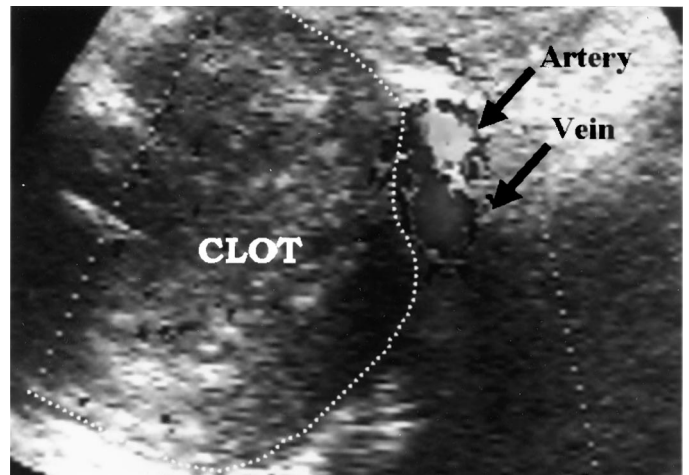


FIGURE 3. Color Doppler US image after injection of 5 mL (5000 U) of thrombin shows complete thrombosis of the pseudoaneurysm (*dotted line*). The right common iliac artery and vein are patent (*arrows*).

evidence of any refilling of the pseudoaneurysm, and the patient was discharged. After 1 month the patient was deemed asymptomatic and a repeat US study confirmed continued absence of flow in the pseudoaneurysm and ruled out recurrence of the lesion.

DISCUSSION

The incidence of pseudoaneurysms after renal transplantation is lower than 1% (1). This complication has been attributed to infection of or failure in the vascular anastomosis which, at the same time, is more frequent in cases of chronic hypertension and hyperlipidemia (3). It is not uncommon for pseudoaneurysms to go unnoticed for a long time or to develop years after the transplantation (3).

Extrarenal pseudoaneurysms may manifest clinically as a large pulsating mass with abdominal pain or may be discovered incidentally. They can also be identified through an accompanying lumbosacral plexopathy (3).

US-guided percutaneous thrombin injection in the treatment of pseudoaneurysms has recently been reported as an efficient and safe procedure (2, 4, 5). Although this technique was originally only used for the treatment of femoral iatrogenic pseudoaneurysms, its range of applications has increased in more recent times (4–6). A search of current literature failed to disclose any other reported cases of the use of US-guided thrombin injection for the treatment of an extrarenal pseudoaneurysm after renal transplantation.

The most significant potential risk of the thrombin injection is the formation of an embolus in the circulation of the distal systemic artery. The risk is reduced by carefully placing the needle tip as far as possible from the neck of the pseudoaneurysm and injecting small amounts of thrombin while maintaining continuous control with the color Doppler (3).

Another potential problem with the use of thrombin injection is the possibility of allergy to products of bovine origin. Pope and Johnston (7) describe a case of anaphylaxis after a bovine thrombin injection in a patient previously exposed to topical bovine thrombin. There are also reports of patients who have had repeated contact with bovine thrombin, developing antibodies that counter bovine factor V. These antibodies can cross-react with human factor V, causing abnormalities in hemostasis (8). Consequently, we avoid indicating bovine thrombin for patients with previous exposure. More recently thrombin of human origin has come into use, which should theoretically reduce the risk of an allergic reaction. However, this source of thrombin is considerably more expensive (8).

A significant dose of thrombin was used to achieve occlusion of the pseudoaneurysm in our patient (5000 U). The quantity of thrombin required to complete the procedure

varies according to the published series. Thus, in a study of 83 patients treated with this technique, there was no correlation between the size of the pseudoaneurysm and the amount of thrombin required for total occlusion (4). In contrast, another report indicates a direct relationship between the size of the pseudoaneurysm and the need for additional doses of thrombin (2).

Surgical treatment of extrarenal pseudoaneurysms is a complex and difficult procedure. Surgery frequently engenders nephrectomy of the transplanted kidney and risk of damage to the recipient vessel (9). Transcatheter embolization with embolizing agents such as metallic coils, polyvinyl, absorbable gelatin powder, or embucilate constitutes an excellent alternative to surgical treatment, although the results are varied. Dorffner et al. (10) report a high percentage of complications, including thrombosis of the renal artery or severe hemorrhage of the anastomosis of the renal artery.

Because of its safety, efficiency, and minimal invasiveness, US-guided percutaneous thrombin injection is, in our opinion, an extremely useful alternative to other treatments such as transcatheter embolization or surgery, both of which are more invasive.

Acknowledgment. The authors thank Lee Boyes for his review of the English manuscript.

REFERENCES

1. Donckier V, De Pauw L, Ferreira J, et al. False aneurysm after transplant nephrectomy. *Transplantation* 1995; 60: 303.
2. Pezzullo JA, Dupuy DE, Cronan JJ. Percutaneous injection of thrombin for the treatment of pseudoaneurysms after catheterization: an alternative to sonographically guided compression. *AJR Am J Roentgenol* 2000; 175: 1035.
3. Luzzio CC, Waclawik AJ, Gallagher CL, Knechtle SJ. Iliac artery pseudoaneurysm following renal transplantation presenting as lumbosacral plexopathy. *Transplantation* 1998; 67: 1077.
4. Kang SS, Labropoulos N, Mansour MA, et al. Expanded indications for ultrasound-guided thrombin injection of pseudoaneurysms. *J Vasc Surg* 2000; 31: 289.
5. Farrel MA, Bruce DR, Bower TC. Sonographically guided percutaneous thrombin injection for treatment of a vein graft pseudoaneurysm. *AJR Am J Roentgenol* 2001; 176: 1032.
6. Sheiman RG, Brophy DP, Perry LJ, Akbari C. Thrombin injection for the repair of brachial artery pseudoaneurysms. *AJR Am J Roentgenol* 1999; 173: 1029.
7. Pope M, Johnston KW. Anaphylaxis after thrombin injection of a femoral pseudoaneurysm: recommendations for prevention. *J Vasc Surg* 2000; 32: 190.
8. Poulson EK, Nelson RC, Mayes CE, Sheafor DH, et al. Sonographically guided thrombin injection of iatrogenic femoral pseudoaneurysms: further experience of a single institution. *AJR Am J Roentgenol* 2001; 177: 309.
9. Koo CK, Rodger S, Baxter GM. Extra-renal pseudoaneurysm: an uncommon complication following renal transplantation. *Clin Radiol* 1999; 54: 755.
10. Dorffner R, Thurner S, Prokesch R, et al. Embolization of iatrogenic vascular injuries of renal transplants: immediate and follow-up results. *Cardiovasc Intervent Radiol* 1998; 21: 129.